

SOF Dentistry

LTC Robert D. Harrington DMD, MPH

ABSTRACT

Special Operations Forces (SOF) medics trained to deliver comprehensive dental care (extractions and fillings) to a population in a contested area can be one of the more important elements in a successful UW campaign. This article will highlight and review an inexpensive, lightweight, highly portable dental system that allows the SOF medic to deliver these vital dental services in the field.

SOF medics properly trained to treat a certain range of dental issues can have a positive impact on the overall mission effectiveness of their deployed team. The most noticeable effect of this training will be with the team's UW mission. The ability of SOF medics to deliver basic dental services (extractions and fillings) to a local population can be one of the most cost effective and productive components in running a successful "hearts and minds" campaign in a contested area. In addition, the ability to definitively treat dental emergencies for associated SOF personnel on deployment can also have a positive impact on unit effectiveness by decreasing the need to MEDEVAC the occasional dental emergency.



This article on the role of SOF dentistry in the UW mission is a compilation of the author's experiences as the Group dentist for the 19th Special Forces Group (Airborne) (SFG(A)) over the past 12 years. This experience includes participating in many multi-week Medical Civil Action Programs (MEDCAPs) in the Pacific region from 1995-2005 and, more significantly, three deployments as the Combined Joint Special Operations Task Force (CJSOTF) dentist in Afghanistan (2004, 2009) and Iraq (2006) with the 3rd, 5th, 7th and 10th Groups. Travelling to over 70 Operational Detachments – Alpha (ODAs) in these three Global War on Terrorism (GWOT) deployments has provided invaluable on-the-ground experiences that have helped determine what dental skills and instruments can be the most useful in the UW mission.

As mentioned above, the running of local health clinics and Village Medical Outreach Program (VMOPs) or MEDCAPs by the ODA at Special Forces (SF) firebases is probably the most effective way to gain local "atmospherics" for an area and to truly connect with the local civilian population. The quality of the medicine that can be delivered in a brief 15 minute encounter can be debated, but the real value is having the local population see the SF members outside of their vehicles and taking a personal interest in their medical problems.

During these UW medical missions with a SOF medical team that has the right skills and equipment, good dental care will be one of the more requested health services by the local population, especially in Afghanistan. This high demand for good

dental care is the result of an almost total lack of competently trained dental personnel of any type in the country (with a few exceptions in the major cities such as Kabul and Herat).

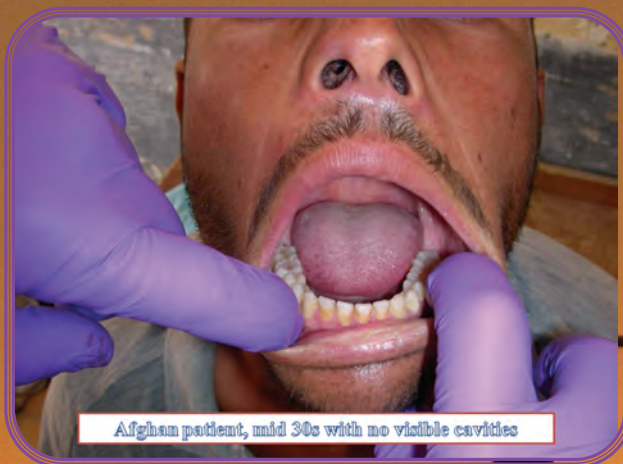The provision of dental care by the SOF medic is a low cost, quick, and definitive procedure that can be delivered in the most austere conditions. This delivery of definitive dental care (fillings or extractions) for an acute problem is a relatively quick and decisive procedure that can contrast with the more indeterminate results on the medical side when providing treatment for chronic, long term conditions like back pain and chronic fatigue.



The author's recent deployments to Iraq and even more so to Afghanistan as the CJSOTF dentist has reinforced this need for SOF medical providers to have the ability to provide both dental extractions and permanent fillings for the local population they treat. All my previous outside the continental United States (OCONUS) deployments were in the Pacific Command (PACOM) region (Fiji, Nepal, Mongolia, Vanuatu, etc.) and the vast majority of dental procedures performed there consisted of extractions. The Central Command (CENTCOM) region experience has been very different, with upwards of 75% of the dental procedures requested and performed on the local population being permanent restorations utilizing a glass ionomer material (FUJI IX).

This regional variance noted in the type of dental procedures requested (extractions vs. fillings) seems to be related to several factors. One important factor affecting the overall demand for dental treatment in an area involves the local diet. Contrary to common belief, the teeth in the more rural and poor areas of the world like Afghanistan, where there is little exposure to refined sugars, are noticeably better than in areas where the diet has a higher exposure to processed, sugar laden foods like sodas and candy.

Upwards of one-third or more of the local Afghans examined during these local VMOPs and at SF clinics had no observable dental decay. Of the re-



maintaining two-thirds, frequently several teeth needed treatment, but there was relatively little note of the rampant decay seen in other areas of the third world, such as the urban areas of Nepal and Honduras (with their higher availability of processed sugars in the diet). Consequently, immediate dental needs in rural Afghanistan were better met by offering a higher ratio of fillings vs. extractions.

A second and more complicated factor that affected this relatively higher demand for fillings vs. extractions was the rural Afghan's time frame of living more day to day with a shorter event horizon than we are used to. Whether the result of the hardships of living in grinding poverty with a certain daily level of danger and uncertainty, the perceived benefits of undergoing a treatment now to resolve a future problem did not seem to be as valued by this rural population.


On innumerable occasions, a patient was seen with a presently quiescent dental abscess and it was explained in depth that it should be extracted to prevent future discomfort and pain. Many patients refused treatment since they explained that it was not hurting at the moment and did not see the need to extract. The ability to offer fillings as an extraction alternative is important since, invariably, the patient would agree to a filling on another decayed tooth.

An effective dental program for the ODA can be very cost effective and time productive. Due to the nature of dental problems, the dentist is generally able to more quickly diagnose and determine treatment options for a dental chief complaint than the medical providers can for their patients. Additionally, the dentist can operate up to six or seven chairs simultaneously and the total time for each definitive dental procedure can be as little as ten minutes.

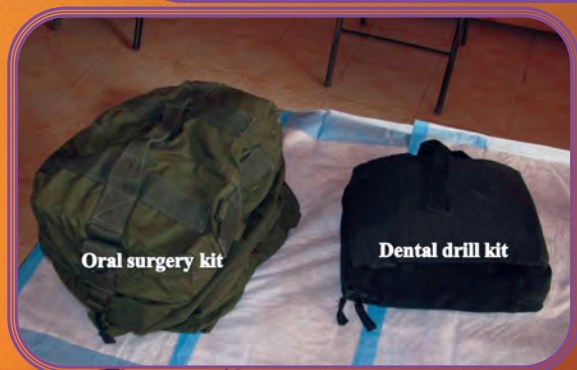THE SOF PORTABLE DENTAL KIT

The primary objective in developing a SOF dental kit was to put together a highly portable system that can be easily carried by one person and be effectively utilized in even the most remote areas where

SOF teams are operating. Especially in rural Afghanistan, movement by air with larger dental systems that require multiple Pelican boxes is very difficult and more time consuming than using our smaller system. Also, modifying the oral surgery and restorative equipment set and adding such items as FUJI IX restorative material and a wider array of exodontia forceps and elevators allows dentists to perform almost all the definitive dental treatments out in the field (both extractions and fillings).



Portable (electric) dental drill setup



Oral surgery kit

Dental drill kit

The current dental kit used on missions in Afghanistan is a modification of components in the Group Dentist Dental Kit and the 18D Dental Tac Set. The SOF Portable Dental Kit can fit into two small bags – the oral surgery and restorative kit fits into one

medic's aide bag and the portable electric dental drill fits into another, smaller case. Everything, including all disposable items like gloves, Cidex® (for cold sterilization when no autoclave available), and gauze, can easily fit into one medium size backpack.

In addition, this compact and light system can be quickly set up and, more importantly, be broken down in only 10 minutes. This is an especially valuable element when one is treating local patients in semi-permissive areas where the security situation can change quickly and a hasty movement may be in order.

COST EFFECTIVENESS OF THE SOF PORTABLE DENTAL KIT

FIXED COSTS CONSIDERATIONS

The now expanded nine Pelican Box 18D Medical Tac Set has a fairly large footprint. With that in mind, this suggested additional dental equipment set comes with only the minimum equipment required to perform those specific dental procedures that are most requested and will not take up much more additional space. Specifically, the Portable Dental Drill Kit (battery powered and minus the optional solar panel and air-water spray system) costs approximately \$2,400 with a government purchase. The Oral Surgery Kit costs about \$1600, depending on how many duplicate forceps and elevators are purchased from the basic list. At a minimum, at least three sets of each should be purchased to allow cold sterilization with Cidex®, when no autoclave is available, and one is planning on regularly incorporating DENTCAPs into their UW mission. The total cost for all durable items will come in under \$5,000.

VARIABLE COST CONSIDERATIONS

The variable cost to perform each dental procedure is also very attractive. For an extraction, the cost should be under \$5 for each individual extraction. Most fillings will cost around \$10 per procedure. The material used for these semi-permanent fillings is FUJI IX, an older generation glass ionomer still used occasionally in the U.S. It is especially effective out at the firebases since it is a hand mixed, powder and liquid material that



Whole kit fits in one mid-size backpack



Fuji IX filling material — powder-liquid combination

doesn't require any powered instruments to complete the mixing or filling process.

The nice thing about this ionomer is that it can be a one-for-one replacement for the ubiquitous intermediate restorative material (IRM) that has been in service with the SOF Medic's Kit for over 40 years. This restoration material has several major advantages over the traditional IRM. It is much easier to teach a novice

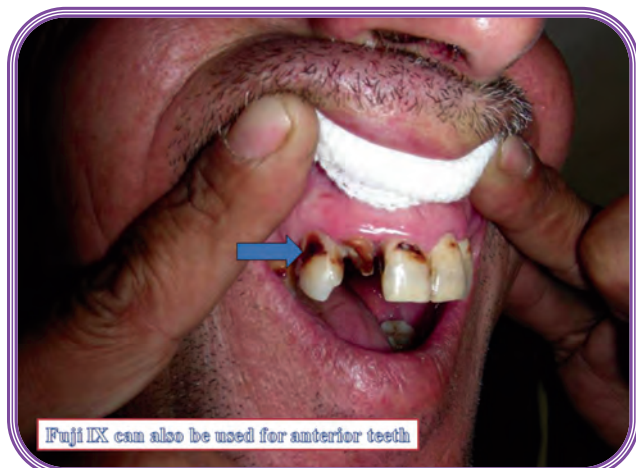ment due to poor air connections; these members could have been lost to the team for up to two weeks or more.

THE PORTABLE SOF DENTAL KIT

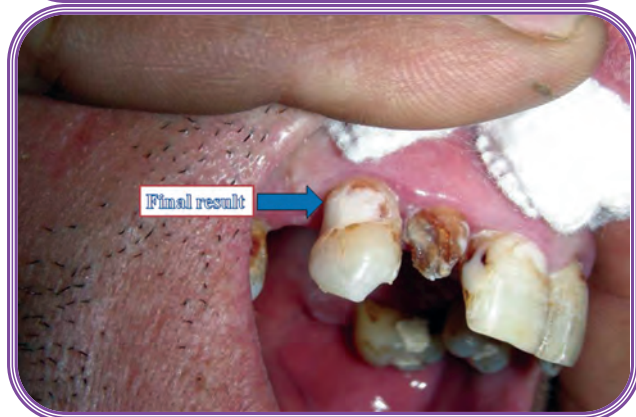
1. Suggested extraction (exodontia) equipment

Since most SOF medics associate dental care for the local population through the usual prism of performing extractions, the oral surgical armamentarium that the author used during these rotations is listed first and appears below. Dentists are usually solo practitioners who additionally are creatures of habit, usually going all the way back to their training in dental school. Therefore, many dentists frequently differ on the best exodontia techniques and instruments to use. The following suggestions are the result of considerable trial and error in the field but with the following eight or nine instruments, one can comfortably say that all regular exodontia techniques can be accomplished in the field by SOF medics.

The general principles of exodontia are pretty standard – giving a local dental anesthetic, using an elevator to loosen the tooth, and then using a variety of forceps to complete the extraction. A suggested technique to deliver this dental anesthesia is with a self-aspirating syringe using a plastic, 27 gauge long or short needle. There are many excellent dental anesthetics



Fuji IX can also be used for anterior teeth

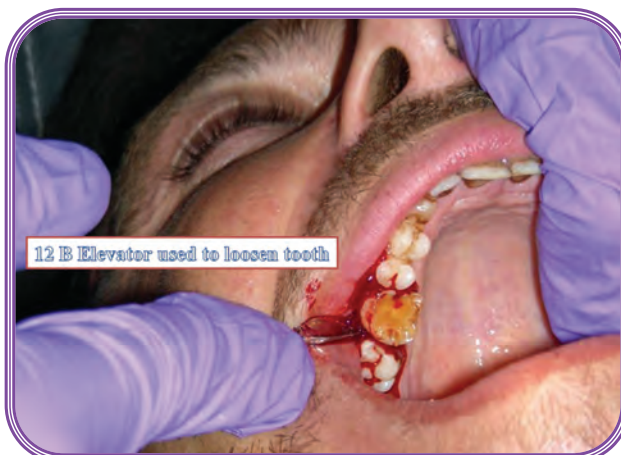

Final result

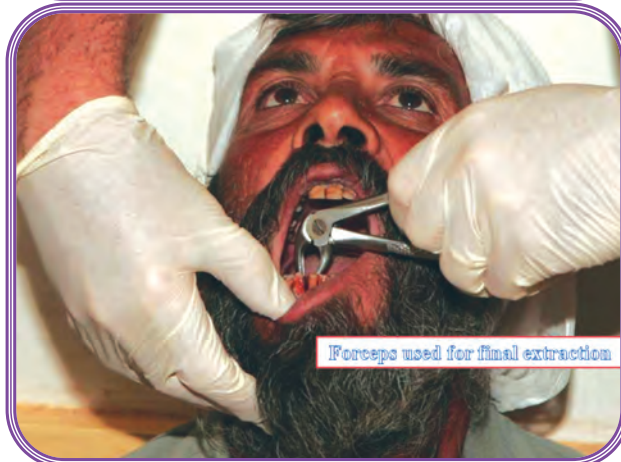to mix it to a proper consistency than the more difficult IRM, it has a much higher compressive strength (to withstand breakage) and actually chemically bonds to the tooth to increase its overall longevity.

All these attractive attributes, including having a white base color that especially works well on front teeth, results in a very long lasting restoration well received by the rural Afghan civilian and military population. It also would be the material of choice for treating SF team members with broken teeth since in most cases FUJI IX will stay bonded to the affected tooth for many months until the team member can rotate back for more definitive care.

During the author's last three GWOT deployments, an average of six to eight U.S./Allied SOF personnel in each rotation were treated for major dental problems out at the firebases, using mostly FUJI IX fillings. Almost all of these more extreme cases would have otherwise required traveling back to the rear for treat-



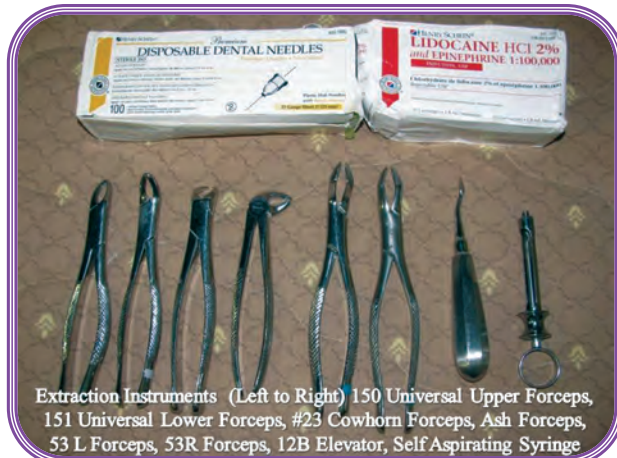
12 B Elevator used to loosen tooth



Forceps used for final extraction

now available, but the most common still in use is 2% lidocaine with 1/100,000 epinephrine, in 1.8ml carpules.

The initial loosening of a tooth to be extracted utilizes some type of elevator. While a great variety in the sizes and shapes of elevators exists, with many dentists touting the benefits of each different style, our suggestion would be the 12B elevator. This one elevator, a favorite of the 18Ds, has the advantage that it can replicate elevator systems that require three or more



specialized instruments. Learning to use one instrument for a beginner seems to work better than trying to master several.

Suggested Forceps: (order with serrated edges for better grip).

150 Universal Upper: For extraction of upper anterior and premolar teeth

151 Universal Lower: For extraction of lower anterior and premolar teeth

Ash Forceps: Also for extracting lower anterior and premolar teeth

Cowhorn #23: For extraction of lower molar (two rooted) teeth

53R, 53L Forceps: For extraction of upper right and left, multi-rooted (usually three root) molars.

Optional exodontia instruments:

144S Forceps

Heidbrink 13/14 Root Tip Pick

If you are planning on scheduling regular and extensive dental related missions while deployed, have at least a minimum of three sets of the above listed instruments so you can properly sterilize them so that you can run a dental clinic for a full day of six to eight hours.

Suggested dental cleaning (prophylaxis) instruments:

13s-14s McCall

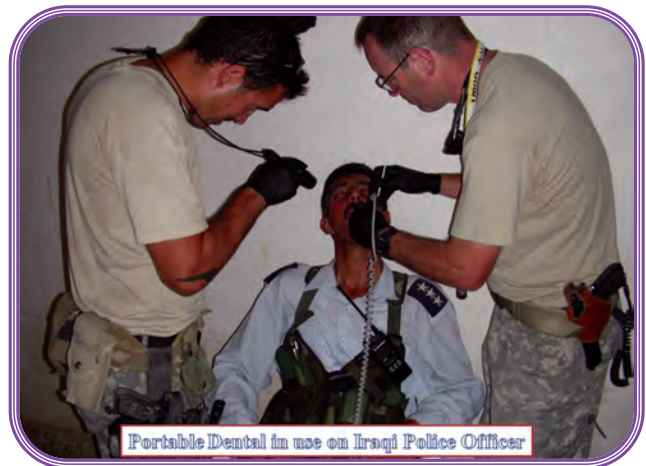Curette Sickle Scalers

Instruments to be used for cleaning of teeth of team members and selected host nation personnel

2. Suggested Dental Restoration Kit

A. The Portable Dental Drill

Being able to use a portable dental drill will greatly expand the ability of the SOF medic to truly offer comprehensive dental care to the local population. The suggestion to add a portable dental drill system to a SOF medic dental kit is not made lightly. One needs to be properly trained in its use, but this recommendation is made confidently after using this system over the past ten years and seeing the successful placement of thousands of restorations by SOF medics after a relatively quick learning curve. In addition, the successful training of selected Afghan and Iraqi army medics in



these same techniques demonstrates that this portable system can also be used as a model to quickly train host nation medical personnel in dental procedures.

The main objective of using the dental drill is to open up a large enough window through the very hard enamel to allow the use of hand instruments to excavate and remove the underlying dentinal decay. This is best accomplished by using the drill under certain limited parameters. The first parameter is to use a relatively short bur such as a #245 (2.4mm) for tooth cutting purposes. By using this relatively short bur, and giving guidance to never cut down more than two-thirds the bur's cutting length, one minimizes the risk of getting too close to the pulp and causing irreversible damage to the tooth.

A second parameter to follow is to only cut in short bursts to prevent the buildup of bur generated heat on the tooth. This is more of a factor when drilling on teeth with small cavities that require the cutting of healthy tooth structure to gain access to the lesion. This is why a water spray is traditionally used in more advanced dental setups to prevent any heat buildup.

The fillings that are visually diagnosed in the field are seen without the benefit of x-rays, so the decay

noted is much more prominent and deep. These deeper cavities, along with short drill bursts, will obviate the need for a more complicated water spray system since these teeth have a greater distance between the vital pulp and the drill access point. However, if one does desire the additional protection of a water spray while drilling, the portable Bell dental system has one available.

B. The Tooth Restoration Process

As we have noted several times, to ensure that one can provide for most dental requests from the local population, especially in Afghanistan, the additional ability to perform simple dental fillings should be included in any dental program run by the SOF medic. Atraumatic Restorative Treatment (ART) technique is a simple, easily learned program of providing permanent dental fillings with glass ionomer cements. This program of instruction has existed for almost 20 years now and is the preferred program for teaching "barefoot dentistry" in third world countries by such organizations as the World Health Organization and the United Nations. In addition to serving the local population, this is an excellent technique for providing definitive dental care to SOF team members in the field since this material actually bonds to tooth structure, as opposed to IRM which simply fills cavitated holes in teeth with little compressive strength.

ATRAUMATIC RESTORATIVE TREATMENT (ART)

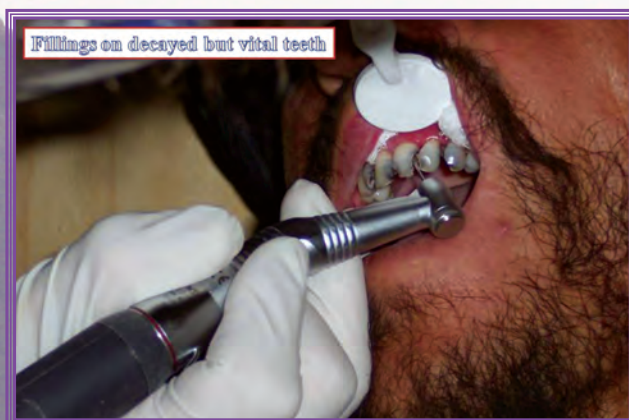
This technique can be used to place simple, permanent fillings on non-infected teeth that have cavities accessible using simple hand instruments or after utilization of the portable dental drill. Teeth that have no pain on percussion are good candidates for this procedure because they are not infected. In addition, treatable teeth can have a history of hot and cold sensitivity but not one of spontaneous pain or facial swelling in the area of the tooth. A final test to help determine tooth vitality is to digitally palpate the outer buccal surface where the tooth root apex is located. No discomfort upon palpation will be an additional indicator of no apical infection.

WHAT YOU NEED

A basic setup to perform ART would include:

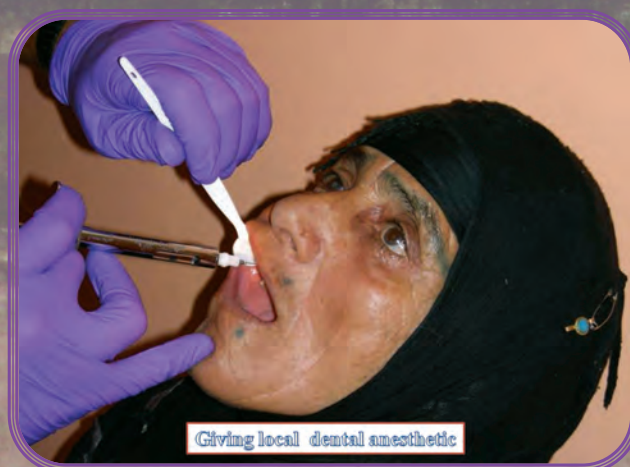- Restorative material: FUJI IX (Posterior Glass Ionomer Restorative Cement)
- Standard package consists of 15g bottle of powder, 8g liquid
- Armamentarium; two to three complete sets of instruments and equipment needed to perform dental anesthesia (dental aspirating syringe, needles, etc.)
- Dental Spatula No. 24
- Spoon Excavator, No. 36/37
- Dental Hatchet
- Woodson Plastic Filling Instrument
- Dental Explorer
- Dental Mirror

- Mixing Pad, Parchment Paper, Dental
- Tofflemire Matrix Bands, (.0010 dead soft)
- Tofflemire Matrix Band Holders
- Small Can, Compressed Air
- Portable, Hand held Electric Dental Drill (30-40; #245 burs)



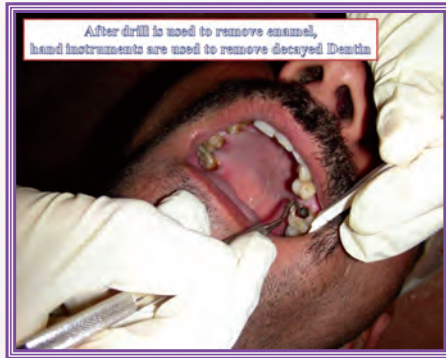WHAT TO DO

1. Proper tooth selection is most important; the tooth that is to be restored must still be vital (hot/cold sensitivity is okay but no spontaneous pain) and have no periapical (root) infection. The best teeth to restore have cavities on the occlusal (chewing) surface or on the roots of the tooth. Secondary sites for restorations are cavities between adjacent teeth.
2. Gain proper local or regional anesthesia in region of tooth to be restored. Note, this ART technique can be used in many cases on teeth that have not been anesthetized or drilled on if the cavitated area is large enough to allow easy access by the spoon excavators.




3. Initially, remove dental enamel overlying decayed tooth structure by using a dental hatchet. When the portable dental drill is available, removal of enamel and decayed dentin is expedited with the drill utilized in circular, cutting motion that does not penetrate any deeper than the cutting surface of the 245 bur.

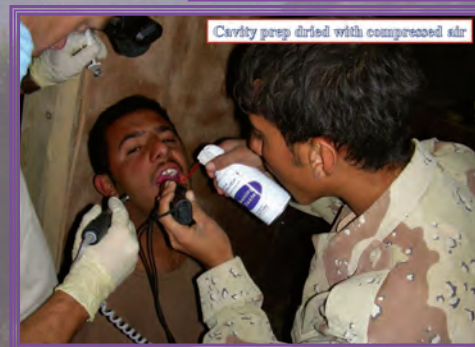4. Use the spoon excavator to remove as much infected dentin as possible after the enamel removal (loose, soft decayed material).



5. Mix equal amounts of FUJI IX powder and liquid with spatula on mixing pad, until material is fairly viscous.



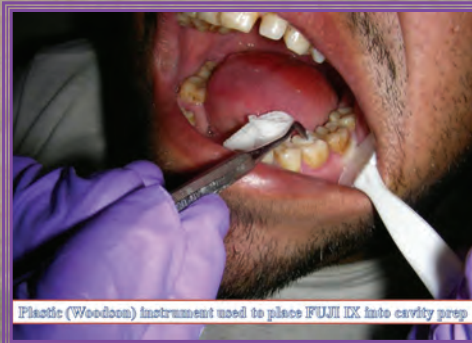6. Dry excavated tooth with quick spray of compressed air from an air can to remove obvious moisture.



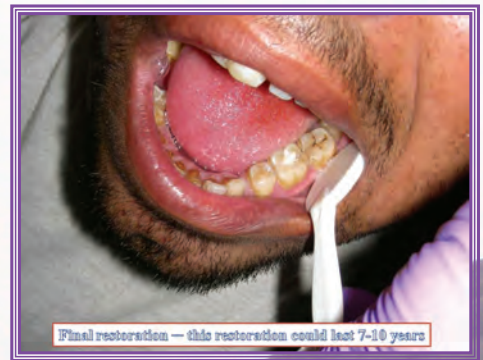7. To help give better retention to the filling, wet inner surface of tooth with FUJI IX liquid using a cotton pellet.

8. Drop the FUJI IX mixture into cavity, using a Woodson instrument. Push FUJI IX into cavity several times with quick jabs of the Woodson, this will help prevent air void formation.

9. Allow filling to set for a few minutes and then wet finger of gloved hand and vigorously rub down filling so it does not protrude above upper surface of tooth. Have patient bite down several times to make sure restoration is not too high.



10. If an interproximal filling is being placed, attempt to use matrix bands to form wall between teeth for proper placement of the FUJI IX material.



11. Group dentist should demonstrate a dozen or more of these restorations before SOF medics attempt their own restorations.



WHAT NOT TO DO

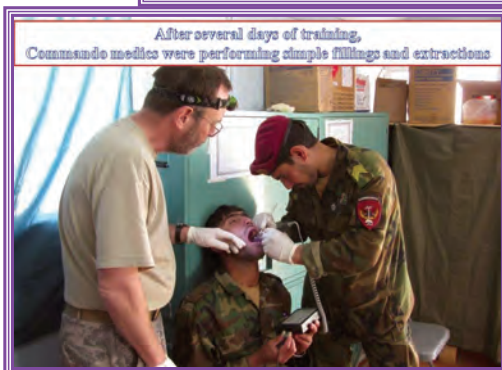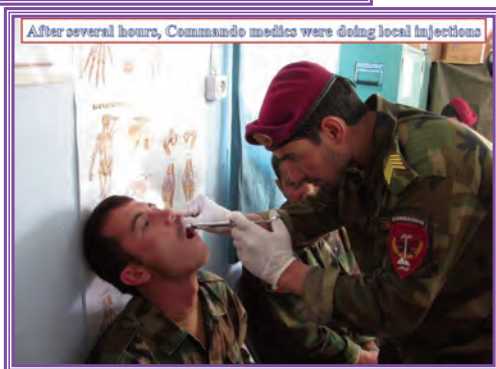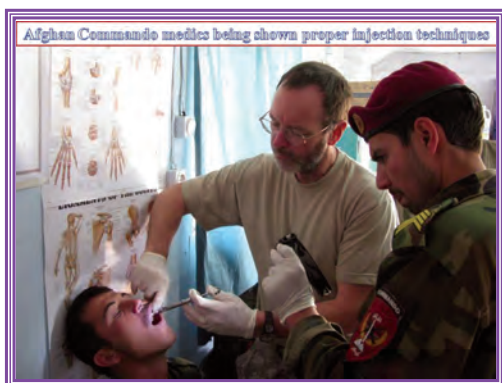This ART works very well and one can gain proficiency relatively quickly. However, there are some things to keep in mind to prevent poor outcomes:

1. Improper tooth selection. Any tooth with a swelling at the apex of the root or is sensitive to percussion is not a suitable candidate.
2. Smaller fillings will have a better long term outcome vs. larger, more complex fillings.
3. Keep area of tooth cavity as dry as possible. No obvious saliva or blood in filling site. The dryer the cavity, the better the longevity of the restoration.
4. On larger fillings, make sure there are no air voids in tooth chamber.
5. ALWAYS make sure the restoration is not TOO HIGH.
6. A major advantage of these glass ionomer fillings is that the mix ratio of powder to liquid can be in a fairly wide range of viscous to fairly runny and still work well. This compares to the more sensitive mixing setting for IRM.

CONCLUSIONS

The portable SOF dental set as described in this article is a low cost, very portable, easily learned system that can deliver significant health benefits to the local population and to SOF team members in need. In addition to being a system that SOF medics can make great use of during their deployments, it can also be used as a template to set up a robust and comprehensive dental program by host nation personnel in even the most remote and poor areas.

Experience from training over 80 Iraqi and Afghan medics on this portable SOF dental system during three tours shows that a more formal dental training program of relatively short length (four to five weeks), utilizing this system, could help alleviate the chronic shortage of properly trained dental personnel in these and other countries.



Finally, this simple system can serve as a good example of developing an "Afghan solution" for an Afghan problem. On many recent tours of Afghan Army medical facilities, most had large western style dental clinics recently installed with powered dental chairs, compressors, and complicated plumbing. Unfortunately, it was frequently noted that large sections of these facilities were falling apart and partially inoperable within a year of installation due to lack of proper training and maintenance. This alternative SOF portable dental kit costs a fraction of the large clinic, requires at most five minutes of easily learned maintenance a day, and will function for years to come with minimal continuing costs. Sometimes simpler (and cheaper) really is better.

Background pictures: Inbound MEDVAC against sunset on Bagram Airfield, Afghanistan and Valley view in Northern Orozgun Province, Afghanistan. *Photos courtesy of LTC Bob Harrington.*



LTC Robert Harrington has served as the Group Dentist for the 19th SFG(A), a National Guard SF unit based at Camp Williams, Utah, for the past 14 years. He received his Doctor of Medical Dentistry from Tufts School of Dental Medicine and his Master of Public Health from Harvard. He recently served on the Joint Editorial Review Board for the 2nd Edition of the SOF Medical Handbook and is the President elect of the Special Operations Medical Association (SOMA). For deployments to Iraq and Afghanistan, he was awarded the Bronze Star Medal, the Joint Service Commendation Medal, and the Combat Medic Badge. He currently maintains a private practice in Weston, MA. He can be reached at robert.dennis.harrington@us.army.mil.